



## CORRESPONDENCE

# Iatrogenic eosinophilic pleural effusion

To the Editor:

Chronic pleural effusions are sometimes difficult to manage. Some cases remain unresolved despite invasive investigations. Iatrogenic pleural effusions are not rare but the diagnosis is mostly putative and difficult to ascertain. Herein, we report two cases of eosinophilic pleural effusions that are potentially iatrogenic and review the current literature accordingly.

A 38-yr-old male, nonsmoker has been followed for 13 yrs in the Dept of Neurology (AP-HM, Marseille, France) for treatment of multiple sclerosis. Until 2 yrs ago he had been treated with bolus of cyclophosphamide, and is currently being treated with 10 mg prednisolone per day, with significant neurological sequelae. His treatment includes prednisolone 10 mg *q.d.*, dantrolene 100 mg *t.i.d.* (doubled 3 months ago), osetemprazole 20 mg *q.d.*, fluoxetine 20 mg *q.d.* and paracetamol in case of pain.

1 month ago the patient noted chest pain and dyspnoea at rest with no other respiratory, extra-thoracic or general symptoms. Chest pain increased leading to hospitalisation in the Dept of Neurology. Clinical examination found no serious organ failure, fever or signs of respiratory distress; however, the pulmonary examination showed a pleural syndrome of the left hemi-thorax. The rest of the physical examination was unremarkable, taking into account the patient's pre-existing neurological sequelae. Laboratory tests showed leukocytosis with 85% of neutrophils without eosinophilia, C-reactive protein (CRP) of 15 mg·L<sup>-1</sup>, brain natriuretic peptide of 20 pg·mL<sup>-1</sup> and normal hepatic, renal, thyroid and adrenal tests. The chest radiograph showed a left pleural effusion, right mediastinal deviation and a blunting of right costophrenic angle, without any associated parenchymal lesion. The computed tomography (CT) scan showed a large left pleural effusion, a small right pleural effusion and a moderate pericardial effusion. The CT scan did not show any parenchymal lesion, except a left lower lobe atelectasis in contact with pleural effusion, and no sign of pulmonary embolism (fig. 1a). Echocardiography confirmed the pericardial effusion without signs of right heart failure and with a good left cardiac function (ejection fraction of 60%). A pleural puncture was performed and 1,500 mL of eosinophilic exudates (eosinophils accounted for 55% of the cells) was drained, the tuberculosis-PCR was negative and cytological examination did not reveal atypical cells. After draining, the pleural effusion re-developed quickly with reconstruction of a left pleural effusion, a moderate right pleural effusion and a slight worsening of pericardial effusion. A second pleural puncture was performed and 1,000 mL of liquid was drained with four pleural biopsies. Histopathological examination showed a nonspecific inflammation with eosinophilic infiltration without granuloma.

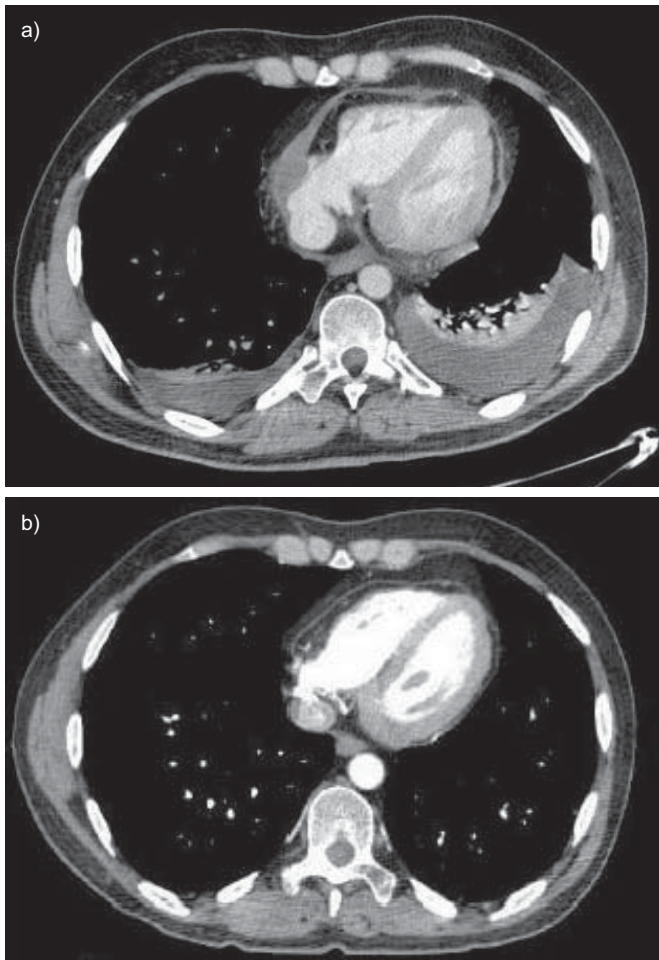
The hypothesis of an iatrogenic pleural effusion was discussed given the absence of a clear cause and the pleural eosinophilia,

especially after the recent doubling of dantrolene. After consulting with his neurologist dantrolene was stopped. The clinical course was favourable, with rapid improvement of pericardial and pleural effusions in 5 days and complete disappearance of the effusions after 10 days (fig. 1b). At 25 days the patient was well without recurrence.

A 53-yr-old male, active smoker (estimated at 30 pack-yrs) was treated for depression without other comorbidities. He was hospitalised in the respiratory department with left chest pain and exertional dyspnoea without other respiratory, extra-thoracic or general symptoms. His current treatment was clomipramine 100 mg *q.d.*, olanzapine 10 mg *q.d.* (started 45 days ago), with dextropropoxyphene plus paracetamol *t.i.d.* in case of pain. The patient presented 3 weeks previously with progressively worsening left chest pain, exertional dyspnoea and dry cough, without fever or other general symptoms. The patient consulted a physician who performed a chest radiograph which showed a moderate left pleural effusion. The clinical examination revealed a pleural syndrome, and the rest of the clinical examination was unremarkable. Laboratory tests showed leukocytes 10 G·L<sup>-1</sup> with 30% eosinophils, CRP of 15 mg·L<sup>-1</sup>, with normal cardiac enzymes and normal hepatic, renal, thyroid and adrenal tests. The CT scan confirmed left pleural effusion with a small pericardial effusion, without parenchymal lesions except for a passive atelectasis of left lower lobe in contact with pleural effusion. There was no sign of pulmonary embolism (fig. 2). Echocardiography showed a small pericardial effusion without compression of right heart cavities, and preserved left ventricular function with an ejection fraction of 60%. Pleural puncture was performed showing an exudate pleural effusion with 75% eosinophils, the cytological examination did not show atypical cells. 2 days later another pleural puncture was performed evacuating 1,200 mL of fluid. Four pleural biopsies were performed and the histopathological examination showed a nonspecific pleuritis with significant eosinophilic infiltrate without granuloma.

This eosinophilic pleural effusion occurred 1 month after the introduction of olanzapine; the hypothesis was iatrogenic effusion. After consulting the patient's psychiatrist olanzapine was stopped. The patient was seen after 2 weeks with a CT scan showing a decrease of pleural effusion and disappearance of pericardial effusion. Laboratory tests showed 200 eosinophils·mm<sup>-3</sup>. 1 month later the patient was fine and the pleural effusion had disappeared.

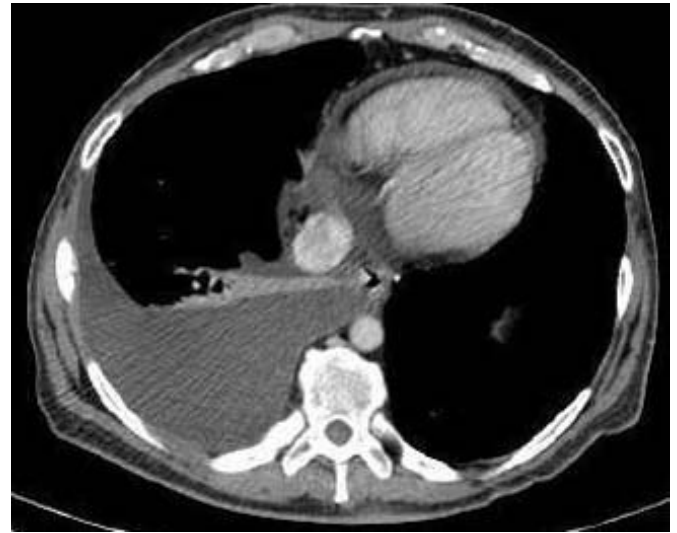Some similarities can be seen with previously reported cases associated with dantrolene, such as onset after chronic administration of dantrolene (>60 days), association with peripheral and pleural fluid eosinophilia, disappearance of symptoms after discontinuation of the drug, and absence of other causes to explain the effusion. All the patients had a disease of the central nervous system without any respiratory dysfunction before the



**FIGURE 1.** A computed tomography scan of a patient a) while receiving dantrolene ( $300 \text{ mg}\cdot\text{day}^{-1}$ ) and b) 10 days after the discontinuation of dantrolene.

initiation of treatment with dantrolene. Respiratory symptoms are always present, including coughing, shortness of breath, chest pain or tachycardia. A low-grade fever ( $38\text{--}38.5^\circ\text{C}$ ) is often noticed [1–3]. Liver function tests were always normal. The pleural tissue biopsies revealed nonspecific inflammation. The chest radiograph always showed a pleural effusion, sometimes bilateral sometimes with associated pericarditis, but never with any other pleural or pulmonary diseases. Lung scan and ventilation–perfusion lung scinti scan ruled out a pulmonary thromboembolic disease. No connective tissue disease was discovered; in two cases antinuclear antibodies were weakly positive with a titre of 1:10, which is not indicative of lupus [2, 3]. We considered the diagnosis of dantrolene-induced pleural effusion to be most likely. The treatment consisted of discontinuing dantrolene and, in one case, adding oral steroid therapy for 2 weeks (prednisone 40 mg daily) because of an early recurrence [4]. No cases of olanzapine-induced pericardial or pleural effusion have been reported to date in the literature, but several cases have been reported after treatment with another atypical antipsychotic, clozapine [5–7].

Eosinophilic pleural effusion, defined as containing  $>10\%$  eosinophils and frequently associated with peripheral eosinophilia, represent 1–9% of all pleural exudates [8]. A cause is



**FIGURE 2.** A computed tomography scan showing a left pleural effusion with a small pericardial effusion.

identified in only 25% of eosinophilic pleural effusion cases [9]. Benign aetiologies include parapneumonic effusions, tuberculosis, benign asbestos pleural effusions, Churg–Strauss syndrome, pulmonary infarction and parasitic disease [10, 11]. It is often the result of air or blood in the pleural cavity [9]. However, malignancy is common: 11 out of 45 eosinophilic effusions were due to cancer in a case series report [11].

An immunological and/or allergic mechanism is strongly suspected in iatrogenic eosinophilic pleural effusions because of the peripheral eosinophilia, the onset after chronic administration of the drug, the recovery after treatment discontinuation and the lack of other explanations despite extensive clinical and paraclinical evaluation [1, 12]. Obviously, a recurrence of the effusion after new administration of the drug would be a strong argument for a diagnosis of certitude, but no such cases are reported [13] mainly for ethical considerations.

Dantrolene sodium is a spasticity reducing drug that acts directly on the long-acting skeletal muscles, without any modification of the nervous conduction or neuromuscular transmission. It inhibits the traffic of intracellular calcium, preventing it from leaving the sarcoplasmic reticulum and therefore inducing a dissociation of the excitation–contraction coupling [13]. It is interesting to note some similarities in chemical structure between nitrofurantoin and dantrolene [14]. Different immunological mechanisms are proposed. There was evidence of *in vitro* lymphocyte sensitivity to nitrofurantoin in a few cases of acute pneumonitis and systemic lupus erythematosus induced by this agent [13, 15, 16]. It is assumed that the pulmonary reactions are mediated by antigen–antibody complexes and studies on immunoglobulin (Ig)G and IgM antibodies and lymphocyte transformation tests have produced conflicting results [17]. Cell-mediated and cytotoxic immune mechanisms can also be implicated [13, 18].

Olanzapine is structurally similar to clozapine and is classified as thienobenzodiazepine. It has a high affinity for dopamine, serotonin, histamine and  $\alpha$ -adrenergic receptors. It is indicated

for the treatment of schizophrenia, delusions and manic bipolar disorder [19]. No cases of pleural disease following treatment with olanzapine have been reported so far in the literature. However, several cases of pulmonary adverse events have been described following treatment with clozapine, including subacute diffuse interstitial pneumonitis and exudate pleural effusions, occasionally eosinophilic [20–23]. We have not found a study that could elucidate the immunological mechanisms of these reactions.

In conclusion, eosinophilic pleural effusion is an uncommon disease in which aetiologies are difficult to establish. We must remember that the eosinophilic pleural effusion is not always benign and may be malignant. Drug-induced eosinophilic pleural effusion is a potential aetiology to search and should be considered as it can be treated easily.

#### K. Alagha, C. Tummino, T. Sofalvi and P. Chanez

Activités ambulatoires du pôle thorax et clinique des bronches, de l'allergie et du sommeil, AP-HM, Laboratoire d'Immunologie INSERM CNRS U 600, UMR6212, Université de la Méditerranée, Marseille, France.

**Correspondence:** K. Alagha, AP-HM, Hôpital Nord, Chemin de Bourelly, 13015 Marseille, France. E-mail: khuder.alagha@ap-hm.fr

**Statement of Interest:** P. Chanez has provided consultancy services for Almirall, Boehringer Ingelheim, Centocor, GlaxoSmithKline, AstraZeneca, Novartis, Teva, Chiesi and Schering Plough; served on advisory boards for Almirall, Boehringer Ingelheim, Centocor, GlaxoSmithKline, AstraZeneca, Novartis, Teva, Chiesi and Schering Plough; received lecture fees from Almirall, Boehringer Ingelheim, Centocor, GlaxoSmithKline, AstraZeneca, Novartis, Teva, Chiesi and Schering Plough; and received industry-sponsored grants from Almirall, Boehringer Ingelheim, Centocor, GlaxoSmithKline, AstraZeneca, Novartis, Teva, Chiesi and Schering Plough.

**Provenance:** Submitted article, peer reviewed.

#### REFERENCES

- 1 Petusevsky ML, Faling LJ, Rocklin RE, *et al.* Pleuropericardial reaction to treatment with dantrolene. *JAMA* 1979; 242: 2772–2774.
- 2 Dohen F, Montagne V, Lelieur E. Pleurésie médicamenteuse au dantrolène: à propos d'un cas [Dantrolene-induced pleurisy: a case report]. *Rev Pneumol Clin* 2000; 56: 261–263.
- 3 Miller DH, Haas LF. Pneumonitis, pleural effusion and pericarditis following treatment with dantrolene. *J Neural Neurosurg Psychiatry* 1984; 47: 553–554.

- 4 Felz MW, Haviland-Foley DJ. Eosinophilic pleural effusion due to dantrolene: resolution with steroid therapy. *South Med J* 2001; 94: 502–504.
- 5 Bhatti MA, Zander J, Reeve E. Clozapine-induced pericarditis, pericardial tamponade, polyserositis, and rash. *J Clin Psychiatry* 2005; 66: 1490–1491.
- 6 Huggins JT, Sahn SA. Drug-induced pleural disease. *Clin Chest Med* 2004; 25: 141–153.
- 7 Boot E, de Haan L, Guzelcan Y, *et al.* Pericardial and bilateral pleural effusion associated with clozapine treatment. *Eur Psychiatry* 2004; 19: 65.
- 8 Light RW, ed. *Pleural Diseases*. 3rd ed. Baltimore, Williams and Wilkins, 1995.
- 9 Adelman M, Albelda SM, Gottlieb J, *et al.* Diagnostic utility of pleural fluid eosinophilia. *Am J Med* 1984; 77: 915–920.
- 10 Wysesbeek AJ, Lahav M, Aelion JA, *et al.* Eosinophilic pleural effusion: a review of 36 cases. *Respiration* 1985; 48: 73–76.
- 11 Martinez-Garcia MA, Cases-Viedma E, Cordero-Rodriguez PJ, *et al.* Diagnostic utility of eosinophils in the pleural fluid. *Eur Respir J* 2000; 15: 166–169.
- 12 Mahoney JM, Bachtel MD. Pleural effusion associated with chronic dantrolene administration. *Ann Pharmacother* 1994; 28: 587–589.
- 13 Lê-Quang B, Calmels P, Valayer-Chaléat E, *et al.* Dantrolene and pleural effusion: case report and review of literature. *Spinal Cord* 2004; 42: 317–320.
- 14 Faling LJ, Petusevsky ML, Snider GL. Nitrofurantoin and dantrolene: liver and lung. *Ann Intern Med* 1980; 93: 151.
- 15 Israel HL, Diamond P. Recurrent pulmonary infiltration and pleural effusion due to nitrofurantoin sensitivity. *N Engl J Med* 1962; 266: 1024–1026.
- 16 Rosenow EC, De Remeé RA, Dines DE. Chronic nitrofurantoin pulmonary reaction. Report of five cases. *N Engl J Med* 1968; 279: 1258–1262.
- 17 Holmberg L, Boman G. Pulmonary reactions to nitrofurantoin: 447 cases reported to the Swedish Adverse Drug Reaction Committee 1966–1976. *Eur J Respir Dis* 1981; 62: 180–189.
- 18 Benard A, Guenanen H, Tillie-Leblond I, *et al.* Pleurésies médicamenteuses [Drug induced pleurisy]. *Rev Mal Resp* 1996; 13: 227–234.
- 19 Association mieux prescrire. Effets indésirables métaboliques de l'olanzapine: procès en cascade aux Etats-Unis [Adverse metabolic effects of olanzapine: cascading trial in the US]. *Rev Prescrire* 2008; 28: 224–226.
- 20 Pan R, John V, Hagg S. Clozapine and pulmonary embolism. *Acta Psychiatrica Scandinavica* 2003; 108: 76–77.
- 21 Stanislav SW, Gonzalez-Blanco M. Papular rash and bilateral pleural effusion, associated with clozapine. *Ann Pharmacother* 1999; 33: 1008–1009.
- 22 Benning TB. Clozapine-induced extrinsic allergic alveolitis. *Br J Psychiatry* 1998; 173: 440–441.
- 23 Chatterjee A, Safferman AZ. Cellulitis, eosinophilia, and unilateral pleural effusion associated with clozapine treatment. *J Clin Psychopharmacol* 1997; 17: 232–233.

DOI: 10.1183/09059180.00000211

## Blind needle biopsy of the pleura: why not?

To the Editor:

We read with great interest the excellent review by JANSSEN [1] in the September issue of the *European Respiratory Review*,

where the author highlights the position of thoracoscopy in the current diagnostic armamentarium of pneumonology and nicely concentrates the up-to-date knowledge in the field.