

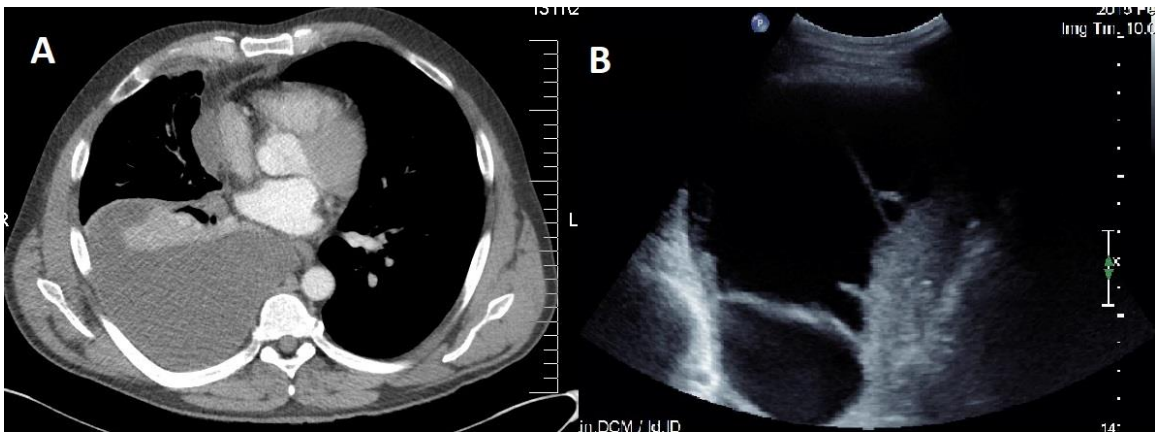Figure S1: A) Coronal CT image shows right pleural effusion without any evidence of septations B) The corresponding ultrasound image reveals the presence of heterogeneous septations.

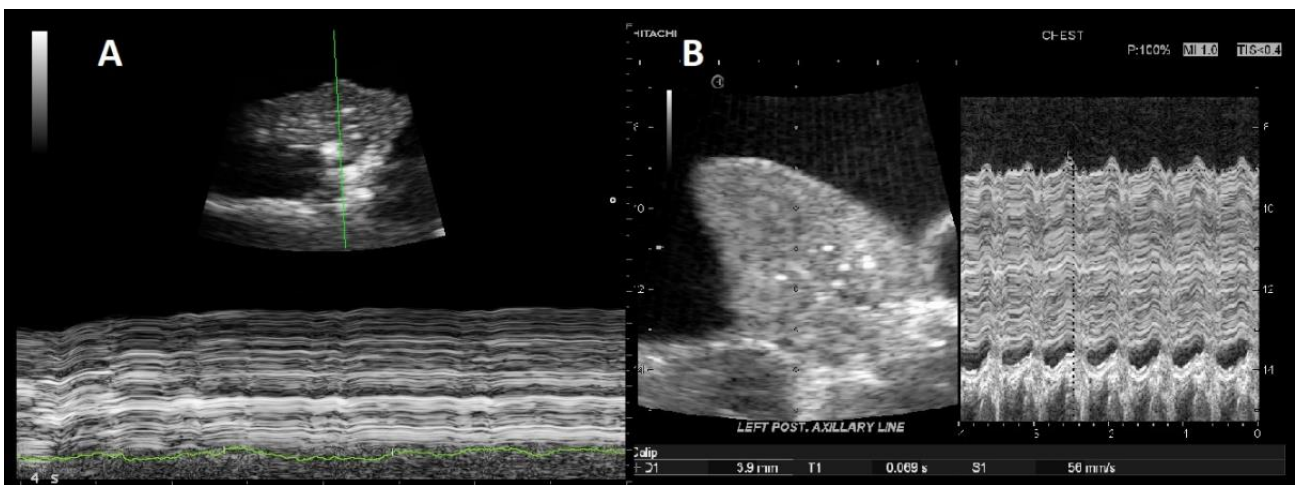


Figure S2: Two examples of M-mode examination of the excursion of the collapsed lung by pleural effusion during breath hold.